

## Hepato-renal and hematological effects of flunixin and silymarin coadministration in rats

I.A. Mohammed<sup>1</sup> , K.A. Shaaban<sup>2</sup>  and Y.M. Albadrany<sup>2</sup> 

<sup>1</sup>Department of Physiology and Pharmacology, Al-Noor University College, <sup>2</sup>Department of Physiology, Biochemistry and Pharmacology, College of Veterinary Medicine, University of Mosul, Mosul, Iraq

### Article information

#### Article history:

Received May 29, 2021

Accepted July 12, 2021

Available online February 4, 2022

#### Keywords:

Flunixin  
Silymarin  
Liver  
Kidney  
Blood analysis

#### Correspondence:

Y.M. Albadrany

[yasser.albadrany@yahoo.com](mailto:yasser.albadrany@yahoo.com)

### Abstract

The study aimed to explore the ameliorative effects of silymarin when administered with flunixin on the liver, kidney, and blood components in rats. The animals were divided into four groups; each one consists of five rats. The first group was served as a control. The second and third groups were treated with silymarin 200 mg/kg b.wt, p.o and flunixin 2.5 mg/kg b.wt, i.p respectively. The fourth group was treated with silymarin and flunixin concurrently. The involved rats were treated for seven consecutive days by a single daily dose. Following the treatment, the biochemical analysis ALT, AST, ALP, Urea, and Creatinine, blood analysis parameters RBC, HGB, HCT, WBC, and PLT, and a histopathological examination liver and kidney were studied for the involved animals. The results showed that flunixin increased the levels of ALT and AST and the concentrations of Urea and Creatinine, and the total number of WBC. Also silymarin caused a remarkable decrease in the flunixin adverse effects on the liver and kidneys. This was reflected from the histological features observed from the diverse tested groups. Based on these findings, the authors concluded that silymarin has the ability to reduce the harmful effects of flunixin on both the liver and the kidneys.

DOI: [10.33899/ijvs.2021.130323.1800](https://doi.org/10.33899/ijvs.2021.130323.1800), ©Authors, 2022, College of Veterinary Medicine, University of Mosul.

This is an open access article under the CC BY 4.0 license (<http://creativecommons.org/licenses/by/4.0/>).

### Introduction

In both human and veterinary medicine, non-steroidal anti-inflammatory drugs (NSAIDs) have been widely used, NSAIDs are one of the world's most commonly used types of medicines and the most widely used analgesics (1). Several NSAIDs are currently available on the market worldwide as over-the-counter (OTC) medications, without any medical prescription and with medication period and dose control carried out only by the patient, without any doctor's supervision. As a result of this mindset, there is a complete lack of medical assessment of the potential hazards and contraindications, length and dosage of treatment with NSAID lead to developed numerous side effects, sometimes severe and sometimes unpredictable (2).

Flunixin, nicotinic acid, 2- (2-methyl-3-trifluoromethylenilino), is an NSAIDs agent which is a

highly replaced nicotinic acid derivative, flunixin was used in veterinary medicine in the late 1970s, *Flunixin meglumine* (FM) is prevented Prostaglandin synthesis and it has effective anti-inflammatory, analgesic besides antipyretic effects and it is widely used in animal diseases such as fever, mastitis, endotoxemia and lameness (3). NSAIDs have been documented to have many adverse effects in horses, humans, dogs, and cats, higher dosages and a longer period of treatment can be needed for severe conditions for this must understanding of the potential side effects associated with a long-term administration of flunixin (4).

In pips, leaves, and fruits, silymarin, the main constituent of milk thistle extract (a set of flavonolignans such as silybin A and B, isosilybin A and B, silibinin, silydianin, and silychristin) is present (5). Silymarin owns antioxidant, anti-inflammatory, antiviral, antifibrotic, and

immunomodulatory function, Studies have shown that silymarin's pharmacological effects are not limited to the treatment of liver diseases. It is also beneficial to protect the pancreas, kidney, myocardium, and central nervous system (6).

Our work aimed to investigate the efficacy of silymarin to mitigate the harmful effects of *Flunixin meglumine* on rats' liver, kidney, and blood components.

## **Materials and methods**

Twenty healthy male albino Wistar rats weighing between 170.00 and 200.00g were obtained from the animal house of the College of Veterinary Medicine, Mosul University. They were housed in plastic cages (five rats per cage). Sawdust was used as litter.

Rats were kept at standard conditions (temperature was  $22\pm 2^{\circ}\text{C}$ , relative humidity of 55-60%, and 12 h light/dark cycle). All the rats fed commercial animal feed produced by the Alnebras Company (Mosul, Iraq), water and food provided *ad libitum*. The study complied with institutional animal use laws, and the rats were given sufficient human care. The scientific board of the Department of Physiology and Pharmacology, Al-Noor University College has appraised and accepted the protocol of study (protocol no. 16/12/2019).

Rats randomly divided into four groups of five rats each using a completely randomized design. Delivery of treatment as a single dose every day for seven consecutive days. Group one rats have received distilled water (volume of injection two ml/kg b.wt) via the intraperitoneal route and tap water (volume of administration 5ml/kg b.wt) via the oral route (delivered to the stomach via gavage needle).

The control group was considered. Group two rats have received Silymarin (21<sup>ST</sup> Century Health Care, USA) at a dose of 200mg/kg b.wt, p.o. Group three rats have received *Flunixin meglumine* (ANVET PHARMA JSC, Vietnam), at a dose of 2.5mg/kg b.wt, i.p. Group four rats have received Silymarin 200mg/kg b.wt, p.o. and *Flunixin meglumine* 2.5mg/kg b.wt, i.p. at the same time.

At the finish of the experiment, twelve-hour after the last treatment. The rats were placed in a closed jar with three paper towels saturated with diethyl ether and held there until they lost their righting reflex, then blood samples (3 ml) were taken via the retro-orbital plexus. Immediately after the blood was drawn, they were executed via decapitation. Two samples of each animal's blood were collected.

The first blood sample was collected in a gel tube to obtain serum for biochemical analysis. The second sample was collected for hematological analysis in a tube containing ethylene diamine tetra-acetic acid (EDTA). Blood and biochemical analysis were performed on the same day of the sample collection. serum biochemical

analysis was performed using a biochemical auto-analyzer device (Dri-ChemNX500 auto analyzer, Fujifilm Corporation, Japan) for biochemical parameters (alanine aminotransferase ALT, aspartate aminotransferase AST, Alkaline phosphatase ALP, Creatinine and Urea).

Blood analyses were performed using a blood coulter auto-analyser device (Mythic 18 Haematology Analyser, orphee-medical corporation, south Australia) for blood analysis parameters (Red blood cells RBC, Haemoglobin HGB, Haematocrit HCT, White blood cells WBC and Platelet PLT).

Two rats from each group were dissected; the liver and kidney samples were taken for the histopathological examination. Specimens were set for 72 hours in 10 percent formalin. Following fixation, the specimens were treated with routine histological processing to obtain 5-6 micrometre ( $\mu\text{m}$ ) thick sections using rotary microtome and stained with Haematoxylin and Eosin (7).

## **Statistical analysis**

Results were evaluated statistically through a one-way analysis of variance (ANOVA) followed by the Least Significant Difference test. Data are expressed as means  $\pm$  standard error. The minimum level of significance was fixed at  $P < 0.05$ .

## **Results**

### **Biochemical findings**

As shown in Table 1, the administration of silymarin, flunixin, and concurrent administration of these two drugs on liver and kidney parameters. Serum ALT, AST, Creatinine and Urea were significantly higher for the flunixin treatment group comparison with the control and silymarin groups.

There was a reduction but not significant in kidney and liver parameters for silymarin plus flunixin group comparison with flunixin group, except creatinine level was significantly decrease.

### **Haematological findings**

As shown in Table 2, the administration of silymarin, flunixin, and concurrent administration of two drugs (silymarin and flunixin) on blood parameters. There was a significant increase in WBC of all groups in compare with control group. RBC, HGB, HCT, and PLT were not significantly different in all treatment groups in compare with the control group.

### **Histopathological examination**

The liver of control and silymarin treated groups revealed normal hepatic lobules, normal center vein, normal portal area, and normal hepatic cell patterns arrangement as shown in figures 1 and 2, respectively.

Table 1: Effect of silymarin, flunixin and silymarin plus flunixin on serum ALT, AST, ALP, Creatinine and Urea levels of rats for seven consecutive days

Groups	ALT U/L	AST U/L	ALP U/L	Creatinine g/dl	Urea mg/dl
Control	47.4±0.92 <sup>a</sup>	140.00±10.32 <sup>a</sup>	777.20±52.20 <sup>a</sup>	0.78±0.051 <sup>ac</sup>	28.50±1.51 <sup>a</sup>
Silymarin	48.0±5.41 <sup>a</sup>	131.00±8.75 <sup>a</sup>	800.40±13.42 <sup>a</sup>	0.72±0.050 <sup>a</sup>	30.50±1.60 <sup>a</sup>
Flunixin	62.40±2.73 <sup>b</sup>	181.20±9.02 <sup>b</sup>	799.00±30.17 <sup>a</sup>	1.26±0.057 <sup>b</sup>	35.03±1.64 <sup>b</sup>
Silymarin+Flunixin	57.40±3.00 <sup>ab</sup>	156.20±7.49 <sup>ab</sup>	549.00±38.17 <sup>b</sup>	0.90±0.036 <sup>ac</sup>	32.15±0.54 <sup>ab</sup>

Values expressed as mean ± S.E. Values with different superscripts letters in the same column are significantly different between groups at  $P < 0.05$ . (Number of rats in each group is five). ALT= alanine aminotransferase, AST=Aspartate aminotransferase, ALP= Alkaline phosphatase.

Table 2: Effect of silymarin, flunixin and silymarin plus flunixin on blood parameters RBC, HGB, HCT, WBC and PLT of rats for seven consecutive days

Groups	RBC 10 <sup>6</sup> /μl	HGB g/dl	HCT %	WBC 10 <sup>3</sup> /μl	PLT 10 <sup>3</sup> /μl
Control	6.77±0.04 <sup>a</sup>	15.12±0.10 <sup>a</sup>	35.84±0.80 <sup>a</sup>	10.60±0.17 <sup>a</sup>	339.80±8.66 <sup>a</sup>
Silymarin	6.77±0.09 <sup>a</sup>	14.92±0.24 <sup>a</sup>	36.98±0.18 <sup>a</sup>	14.14±0.26 <sup>b</sup>	334.00±16.49 <sup>a</sup>
Flunixin	6.28±0.30 <sup>a</sup>	15.82±0.29 <sup>a</sup>	36.36±1.09 <sup>a</sup>	15.02±0.26 <sup>b</sup>	312.60±30.20 <sup>a</sup>
Silymarin+Flunixin	6.54±0.34 <sup>a</sup>	15.92±0.42 <sup>a</sup>	36.74±1.93 <sup>a</sup>	14.58±0.65 <sup>b</sup>	326.40±21.97 <sup>a</sup>

Values expressed as mean ± S.E. Values with different superscripts letters in the same column are significantly different between groups at  $P < 0.05$ . (Number of rats in each group is five). RBC= Red blood cells, HGB= Hemoglobin, HCT= Hematocrit, WBC= White blood cells and PLT= Platelet.

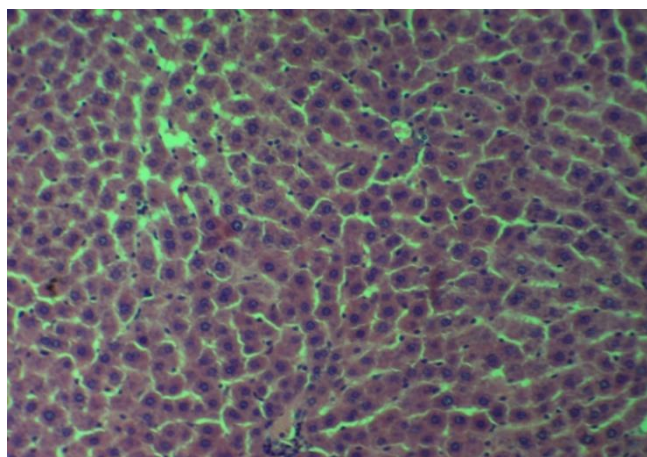


Figure 1: Section of the liver of the rat from the control group showing normal histological hepatic features of liver. H&E stain. 100 X.

The section of the rats' liver treated with flunixin shows moderate fatty change with swelled hepatocyte containing vacuoles (vascularized cytoplasm), multiple apoptotic figures clearly noticed, and change in the normal hepatic cords patterns (Figure 3). Liver section of rats treated with flunixin and silymarin shows mild sinusoidal congestion and mild change in the normal hepatic cords patterns (Figure 4).

The kidney of control and silymarin treated groups shown normal histology (Figures 5 and 6). The kidney section of rats treated with flunixin shows cloudy swelling

of the renal tubular cells, the lumen of renal tubules contains eosinophilic fluid reflecting protein urea, congested renal capillary, mild inflammatory infiltration (Figure 7).

Sever congestion with inflammatory infiltration, interstitial oedema, dilatation of tubules (Figure 8). The kidney of the group treated with flunixin and silymarin revealed to moderate cloudy swelling of the renal tubular cells with inflammatory cell infiltrations (Figure 9).

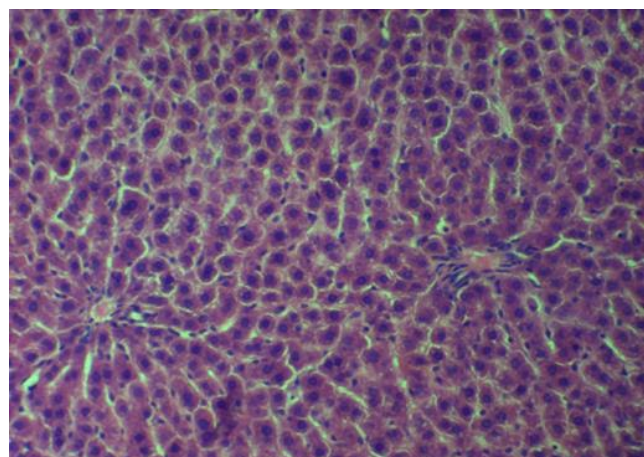


Figure 2: Section in the liver of rat from silymarin treated group showing normal cells pattern arrangement. H&E stain. 100 X.



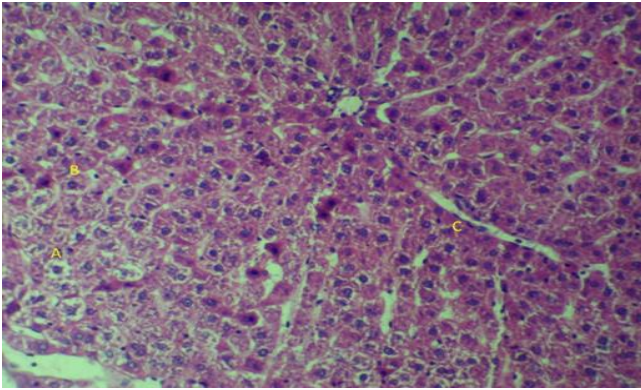


Figure 3: Section of the liver of rat from flunixin treated group showing acute cell swelling manifested by vacuolated hepatocytes (A) with increase occurrence of apoptotic figures in the hepatocytes (B) the proliferation of kupfer cells (C). H&E stain. 100 X.

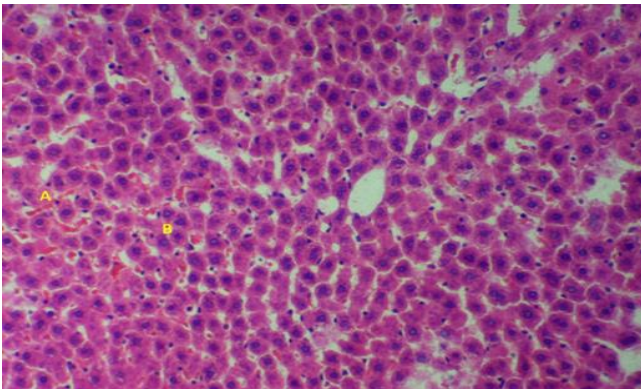


Figure 4: Section of the liver of rat from flunixin and silymarin group showing mild hepatocyte swelling without obvious vacuolation (A), mild sinusoidal congestion (B) and mild change in the normal hepatic cords pattern. H&E stain.100X

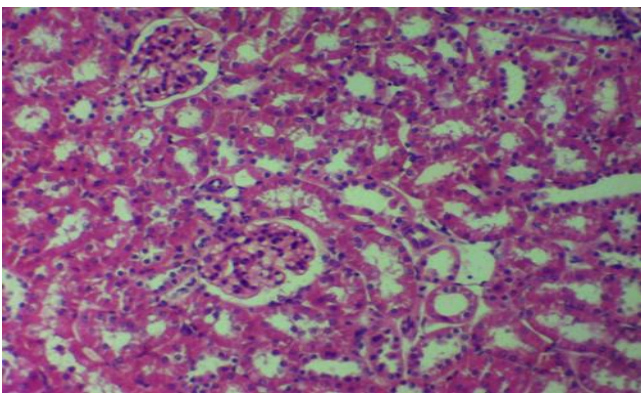


Figure 5: Section of rat kidney from control group showing normal histological features. H&E stain. 100 X.

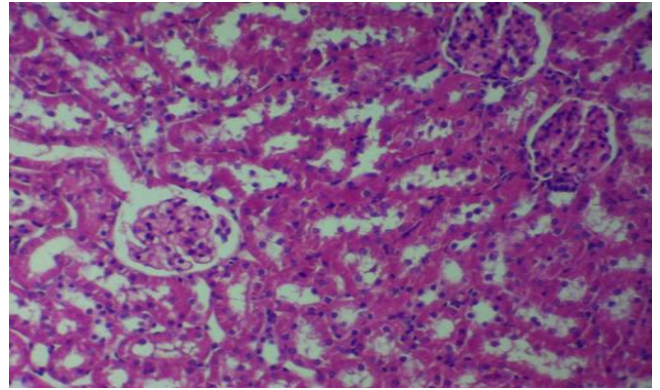


Figure 6: Rat kidney from silymarin treated group showing normal tubular and normal glomerulus. H&E stain. 100 X.

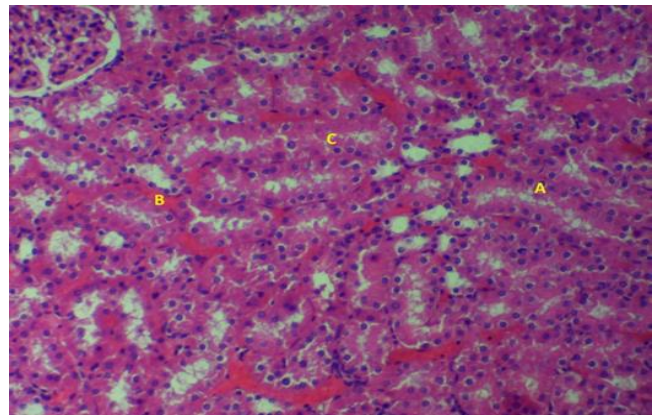


Figure 7: Rat kidney from flunixin treated showing cloudy swelling of the renal tubular cells (A), congested blood vessels (B) eosinophilic urine (C). H&E stain. 100 X.

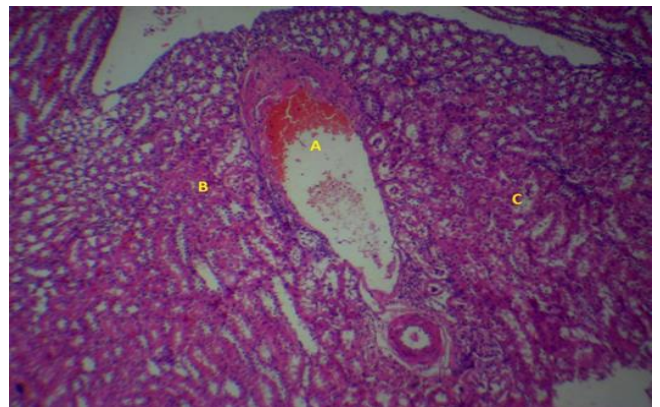


Figure 8: Rat kidney from flunixin treated group showing congestion (A) cloudy swelling (B) with eosinophilic urine (C). H&E stain. 4 X.



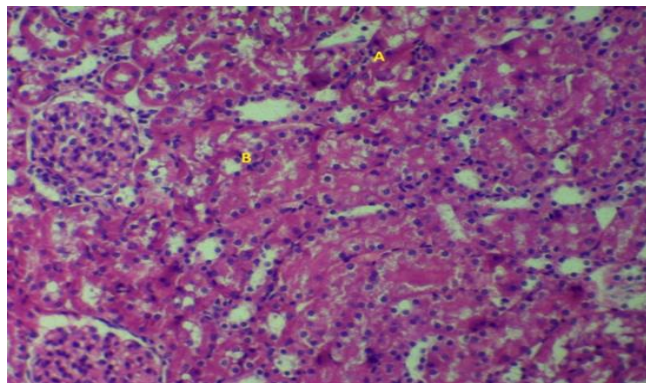


Figure 9: Section of the kidney of rat from flunixin and Silymarin revealing mild to moderate cloudy swelling (A) and mild inflammatory cell infiltrations (B). H&E stain. 100 X.

## Discussion

Through the results of the study, there were harmful effects of flunixin on the liver and kidneys represented by the high level of ALT, AST, Creatinine and Urea, As well as the pathohistological changes in both liver and kidneys. To discuss these harmful effects of flunixin, we must know the mechanism of action of flunixin.

*Flunixin meglumine* blocks both cyclooxygenase-1 (COX-1) and COX-2 non-selectively and it is approved for the treatment of numerous inflammatory and non-inflammatory diseases such as arthritis, post-operative and post-traumatic pain in human and animal (8). Cyclooxygenase (COX) converts arachidonic acid into prostanoids such as prostaglandins (PGs), prostacyclines, and thromboxane. Prostanoids are the key mediators that control different functions in the gastrointestinal, cardiovascular, urogenital and nervous systems, also play a critical role in the immunity and inflammation (9).

The functions of COX-1 are regulate the renal hemodynamics and glomerular filtration while the functions of COX-2 are the elimination of water and salt (10). The level of creatinine besides urea is an indicator of renal activity, but the creatinine test is more sensitive than urea (11). The rise in creatinine and urea concentration can be due to the inhibition of the COX-1 enzyme, and therefore a reduction in the prostaglandin synthesis and this leads to a decrease in the rate of glomerular filtration and hemodynamic of the kidneys, and thus a decrease in the excretion of creatinine and urea.

By altering the renal hemodynamic status due to COX inhibition, NSAIDs induce acute kidney injury and trigger changes in kidney structures, such as damage of brush border, tubules dilatation, and development of tip lesions, which are revealing of kidney damage (12). Flunixin is responsible for developing renal papillary necrosis in

horses, renal tissue necrosis in dogs, and related findings have been reported in quails and budgerigars (13).

The development of active metabolites is correlated with the nephrotoxicity process of NSAIDs. With the involvement of cytochrome P-450, electrophilic intermediates metabolite have produced that bind covalently to macromolecules of the cell which disturb mitochondrial and nuclear roles triggering the development of ROS and protein oxidation (14). The body's inability to remove the ROS promptly via the antioxidant mechanism lead to oxidative stress (15). ROS are considered to be responsible for destroying the membrane of the mitochondria and releasing Cyt C (16). Disbalances between the antioxidant ability of the cell and the production of ROS can lead to irreversible damage to cell macromolecules and cause cell death due to apoptosis and necrosis (17).

It is imperative to understand that NSAIDs can potentially contribute to two main hepatotoxicity clinical forms: first, acute hepatitis (characterized by jaundice, nausea and fever along with elevated serum transaminase levels), whereas second form, chronic active hepatitis (characterized by serological besides histopathological abnormalities) (18).

Mitochondrial damage has been due to the toxicity of many NSAIDs as a general mechanism. The lipophilic and weakly acidic drugs can easily enter the outer membrane of the mitochondria then action as protonophores, shutting protons back into the matrix from the intermembrane space via the inner membrane of the mitochondria, a cellular energy crisis is the result of mitochondrial uncoupling of oxidative phosphorylation then, cell death (19). NSAIDs also raises the intracellular accumulation of various pro-apoptotic proteasomal substrates, such as Bax, I $\kappa$ B- $\alpha$ , p53, p21waf1/Cip1 and p27ki, resulting in cell cycle arrest and apoptosis (20).

The increase in the total number of white blood cells may be related to the mechanism of action of flunixin, as it decreases the prostaglandins synthesis from arachidonic acid (the main substrate) by inhibiting cyclooxygenase, which leads to the availability of the arachidonic acid as the substrate to the lipooxygenase enzyme leading to increased production of leukotrienes. As we have known, Leukotrienes are active chemical attractants that trigger white blood cell movement (21).

Through the results we obtained, silymarin was able to reduce the harmful effects of flunixin on both the kidneys and the liver. It has a low toxicity, potent antioxidant, and regenerative activity for that reason silymarin has gained attention for medicinal usage (22).

Various mechanistic reasons have been identified for the antioxidant effects of silymarin, including (I) Preventing the development of free radicals by inhibiting enzyme-producing specific reactive oxygen species (ROS) or enhancing the integrity of mitochondria in conditions of

stress (II) reducing inflammatory reactions by preventing nuclear factor  $\kappa$ B (NF- $\kappa$ B)-dependent pathways, and (III) preserving an ideal redox balance enzymes and non-enzymatic antioxidants, primarily through the stimulation of nuclear factor-erythroid two-related factor in the cell by activating a variety of antioxidant (23).

Silymarin modulates oxidative stress caused by doxorubicin through down regulation of Bcl-xL, and p53 expression, thus preventing liver apoptotic and necrotic cell death (24). In kidney, cells harmed by paracetamol, cisplatin, and vincristin in vitro, silybin administration before or after chemical-induced injury have been shown to mitigate or prevent nephrotoxic effects (25).

## Conclusion

We conclude that silymarin has the ability to reduce the harmful effects of flunixin on both the liver and kidneys, which gives a clear impression on the possibility of using silymarin as an accompanying drug with flunixin, especially in the long therapeutic periods.

## Acknowledgements

Many thanks to the College of Veterinary Medicine, University of Mosul for all the facilities provided for the completion of the research, with sincere thanks and appreciation to Dr. Karam Al-Mallah for interpretation the histological sections.

## Conflict of interest

The authors state no competing interests.

## References

1. Wehling M. Non-steroidal anti-inflammatory drug use in chronic pain conditions with special emphasis on the elderly and patients with relevant comorbidities: management and mitigation of risks and adverse effects. *Eur J Clin Pharmacol*. 2014;70(10):1159-1172. DOI: [10.1007/s00228-014-1734-6](https://doi.org/10.1007/s00228-014-1734-6)
2. Donati M, Conforti A, Lenti MC, Capuano A, Bortolami O, Motola D, et al. Risk of acute and serious liver injury associated to nimesulide and other NSAIDs: data from drug induced liver injury case-control study in Italy. *Br J Clin Pharmacol*. 2016;82(1):238-248. DOI: [10.1111/bcp.12938](https://doi.org/10.1111/bcp.12938)
3. Yazar E, Er A, Uney K, Altunok V, Elmas M. Effect of *Flunixin meglumine* on cytokine levels in experimental endotoxemia in mice. *J Vet Med Ser A*. 2007;54(7):352-355. DOI: [10.1111/j.1439-0442.2007.00959.x](https://doi.org/10.1111/j.1439-0442.2007.00959.x)
4. Erdogan HM, Gunes V, Gokce HI, Uzun M, Cital M, Yuksek N. Effects of prolonged intravenous *Flunixin meglumine* in healthy dogs. *Acta Vet Brno*. 2003;72(1):71-78. DOI: [10.2754/avb200372010071](https://doi.org/10.2754/avb200372010071)
5. Soleimani V, Delghandi PS, Moallem SA, Karimi G. Safety and toxicity of silymarin, the major constituent of milk thistle extract: An updated review. *Phyther Res*. 2019;33(6):1627-1638. DOI: [10.1002/ptr.6361](https://doi.org/10.1002/ptr.6361)
6. Naser AS, Amin YM. Analgesic effect of silymarin in chicks. *Iraqi J Vet Sci*. 2019;33(2):273-276. DOI: [10.33899/ijvs.2019.162906](https://doi.org/10.33899/ijvs.2019.162906)
7. Al-Sabaawy HB, Rahawi AM, Al-Mahmood SS. Standard techniques for formalin-fixed paraffin-embedded tissue: A Pathologist's perspective. *Iraqi J Vet Sci*. 2021;35(Suppl I-III):127-135. DOI: [10.33899/ijvs.2021.131918.2023](https://doi.org/10.33899/ijvs.2021.131918.2023)
8. Jarolmasjed S, Shahbazfar A-A, Mohammadpour H. Histopathological Anti-inflammatory Effects of *Flunixin meglumine* and Ketoprofen on Excised Rat Tendon. *Iran J Vet Surg*. 2015;10(1):53-58. [\[available at\]](#)
9. Kirkby NS, Chan M V., Zaiss AK, Garcia-Vaz E, Jiao J, Berglund LM, et al. Systematic study of constitutive cyclooxygenase-2 expression: Role of NF- $\kappa$ B and NFAT transcriptional pathways. *Proc Natl Acad Sci U S A*. 2016;113(2):434-439. DOI: [10.1073/pnas.1517642113](https://doi.org/10.1073/pnas.1517642113)
10. Weir M. Renal effects of nonselective NSAIDs and coxibs. *Cleve Clin J Med*. 2002;69(1):53-58. DOI: [10.3949/CCJM.69.SUPPL.1.S153](https://doi.org/10.3949/CCJM.69.SUPPL.1.S153)
11. Vasudevan DM, Sreekumari S. Textbook of biochemistry for medicinal students 5<sup>th</sup> ed. New Delhi: Jaypee Brother Med Publ Ltd; 2007. 535 p. DOI: [10.5005/jp/books/13014](https://doi.org/10.5005/jp/books/13014)
12. Ejaz P, Bhojani K, Joshi VR. NSAIDs and kidney. *JAPL*. 2004;52:632-639. [\[available at\]](#)
13. Ramzan M, Ashraf M, Mahmood KT. Toxicity of *Flunixin meglumine* in broiler chickens. *J Pharm Sci Res*. 2012;4(2):1748-1758. [\[available at\]](#)
14. Lee V, Bakirova R, Muravlyova L, Turkhanova Z, Rakhmetova A. Drug-induced nephropathy and molecular patterns of oxidative stress. *Open Access Maced J Med Sci*. 2020;8(B):205-209. DOI: [10.3889/oamjms.2020.3559](https://doi.org/10.3889/oamjms.2020.3559)
15. Barwarei B. Histopathological effect of fluoxetine drug on the brain of pregnant mice and their embryos. *Iraqi J Vet Sci*. 2020;34(1):71-76. DOI: [10.33899/ijvs.2019.125467.1006](https://doi.org/10.33899/ijvs.2019.125467.1006)
16. Hassan AA, Asim RA. Effect of vitamin C and acetylsalicylic acid supplementation on some hematological value, heat shock protein 70 concentration and growth hormone level in broiler exposed to heat stress. *Iraqi J Vet Sci*. 2020;34(2):357-363. DOI: [10.33899/ijvs.2019.125950.1195](https://doi.org/10.33899/ijvs.2019.125950.1195)
17. Mustafa KA, Al-Baggou BK. Toxicological and neurobehavioral effects of chlorpyrifos and deltamethrin insecticides in mice. *Iraqi J Vet Sci*. 2020;34(1):189-196. DOI: [10.33899/ijvs.2019.125738.1144](https://doi.org/10.33899/ijvs.2019.125738.1144)
18. O'connor N, Dargan PI, Jones AL. Hepatocellular damage from non-steroidal anti-inflammatory drugs. *QJM*. 2003;96(11):787-791. DOI: [10.1093/qjmed/hcg138](https://doi.org/10.1093/qjmed/hcg138)
19. Al-Abdaly YZ, Saeed MG, Al-Hashemi HM. Effect of methotrexate and aspirin interaction and its relationship to oxidative stress in rats. *Iraqi J Vet Sci*. 2021;35(1):151-156. DOI: [10.33899/ijvs.2020.126490.1335](https://doi.org/10.33899/ijvs.2020.126490.1335)
20. Jana NR. NSAIDs and apoptosis. *Cell Mol life Sci*. 2008;65(9):1295-1301. DOI: [10.1007/s00018-008-7511-x](https://doi.org/10.1007/s00018-008-7511-x)
21. Paino IMM, Ximenes VF, Da Fonseca LM, Kanegae MPP, Khalil NM, Brunetti IL. Effect of therapeutic plasma concentrations of non-steroidal anti-inflammatory drugs on the production of reactive oxygen species by activated rat neutrophils. *Brazilian J Med Biol Res*. 2005;38(4):543-551. DOI: [10.1590/s0100-879x2005000400007](https://doi.org/10.1590/s0100-879x2005000400007)
22. Milić N, Milošević N, Suvajdžić L, Žarkov M, Abenavoli L. New therapeutic potentials of milk thistle (*Silybum marianum*). *Nat Prod Commun*. 2013;8(12):1801-1810. DOI: [10.11772F1934578X1300801236](https://doi.org/10.11772F1934578X1300801236)
23. tolf AM, Cardoso CC, Acco A. Effects of silymarin on diabetes mellitus complications: A review. *Phyther Res*. 2017;31(3):366-374. DOI: [10.1002/ptr.5768](https://doi.org/10.1002/ptr.5768)
24. Patel N, Joseph C, Corcoran GB, Ray SD. Silymarin modulates doxorubicin-induced oxidative stress, Bcl-xL and p53 expression while preventing apoptotic and necrotic cell death in the liver. *Toxicol Appl Pharmacol*. 2010;245(2):143-152. DOI: [10.1016/j.taap.2010.02.002](https://doi.org/10.1016/j.taap.2010.02.002)
25. Sonnenbichler J, Scalera F, Sonnenbichler I, Weyhenmeyer R. Stimulatory effects of silibinin and silicristin from the milk thistle *Silybum marianum* on kidney cells. *J Pharmacol Exp Ther*. 1999;290(3):1375-1383. [\[available at\]](#)

مجموعة). المجموعة الأولى كانت بمثابة السيطرة. تم معالجة المجموعتان الثانية والثالثة بالسليمارين ٢٠٠ ملغم / كغم والفلونكسين ٢,٥ ملغم / كغم على التوالي. عوملت المجموعة الرابعة بالسليمارين والفلونكسين في نفس الوقت. امتدت فترة المعاملة لسبعة أيام متتالية بجرعة واحدة في اليوم. بعد المعاملة تم اجراء التحليل الكيميائي الحيوي لخميرة الالنين ناقل الأمين وخميرة الاسبارتيت ناقل الأمين وخميرة الفوسفاتيز القلوية واليوريا والكرياتينين، وتحليل معلمات الدم وتمثلت بكريات الدم الحمر وخضاب الدم وحجم الخلايا المكذسة وكريات الدم البيضاء والصفائح الدموية، والفحص النسيجي للكبد والكلى في جميع المجاميع. أظهرت النتائج أن الفلونكسين رفع من مستويات خميرة الالنين ناقل الأمين وخميرة الاسبارتيت ناقل الأمين وتركيز اليوريا والكرياتينين وكذلك زيادة كبيرة في إجمالي عدد كريات الدم البيضاء. كما اظهر السليمارين انخفاض ملحوظ في التأثيرات الضارة للفلونكسين على الكبد والكلى. وعكست المقاطع النسيجية المأخوذة من المجاميع المختلفة هذه النتائج. نستنتج من الدراسة أن السليمارين لديه القدرة على تقليل الآثار الضارة للفلونكسين على كل من الكبد والكلى.

## التأثيرات الكبدية-الكلوية والدموية للإعطاء المتزامن للفلونكسين والسليمارين في الجرذان

امتثال علي محمد<sup>١</sup> وخالد احمد شعبان<sup>٢</sup>  
وياسر محمدا مين البدراني<sup>٢</sup>

<sup>١</sup> فرع الفلسفة والأدوية، كلية النور الجامعة، فرع الفلسفة والكيمياء الحياتية والأدوية، كلية الطب البيطري، جامعة الموصل، الموصل، العراق

### الخلاصة

هدفت الدراسة إلى الكشف عن التأثيرات التحسينية للسليمارين عند الإعطاء المتزامن مع الفلونكسين على كل من الكبد والكلى ومكونات الدم في الجرذان. قسمت الجرذان إلى أربع مجاميع (خمسة /