






## Effect of sodium benzoate on some biochemical, physiological and histopathological aspects in adult male rats

S.A. Al-Ameen<sup>1</sup>, E.H. Jarjees<sup>2</sup> and F.Kh. Tawfeeq<sup>3</sup>

<sup>1</sup>Department of Chemistry, Science College, University of Mosul, <sup>2</sup>Department of Dental Industry Techniques, Al-Noor University College, <sup>3</sup>Department of Biochemistry, Physiology and Pharmacology, College of Veterinary Medicine, University of Mosul, Mosul, Iraq

### Article information

#### Article history:

Received April 14, 2021

Accepted July 11, 2021

Available online March 3, 2022

#### Keywords:

Sodium benzoate

Growth hormone

Nitric oxide

#### Correspondence:

E.H. Jarjees

[eman.hazim@alnoor.edu.iq](mailto:eman.hazim@alnoor.edu.iq)

### Abstract

Sodium benzoate (SB) is a white powder, used as preservative and food additive. Biochemical, physiological and histopathological effects of SB been tested in adult male rats. Twenty-four adult albino male rats aged 100 day and weighted 250-350 g were used. Animals were divided into four groups. The first group considered as control, which received normal saline orally, other groups treated with SB by 300, 400 and 500 mg/kg of body weight respectively for 30 days. At the end of experiment, blood samples were collected from retro orbital sinus. Heart, liver, spleen, kidneys and brain were obtained for weight recording. The results indicated a significant decrease of super oxide dismutase SOD activity and a significant increase of nitric oxide NO level of treated group 500 mg/kg of body weight. Moreover, findings revealed that there are no significant changes in growth hormone GH activity and body weight. A significant reduction of heart weight of treated group 500 mg/kg of body weight were observed. The histopathological changes ranged from mild to severe in the brain cortex, as focal gliosis, satellitosis, mild vacuolation and vasogenic edema in treated groups with SB by different doses. Also, some changes were observed in liver represented by congestion of portal vein, mild hydropic degeneration of hepatocytes, stenosis of sinusoids, steatosis and necrosis of hepatocytes in treated groups with SB compared to control group. It concluded that short-term exposure to high doses of SB may be considered an oxidant substance that caused oxidative stress. Furthermore, SB can harm various organs in the body.

DOI: [10.33899/ijvs.2021.129935.1705](https://doi.org/10.33899/ijvs.2021.129935.1705), ©Authors, 2022, College of Veterinary Medicine, University of Mosul.

This is an open access article under the CC BY 4.0 license (<http://creativecommons.org/licenses/by/4.0/>).

### Introduction

Many people, during the huge advances which have happened in technology and daily lifestyle as they are in age of speed, turn to use fast and prepackaged foods which is sold in markets rather than preparing them at homes with no consideration to what they contain of added materials, which are changing or damaging their qualities, also they generally cause health problems (1). On the other hand, these materials play an important role in keeping these types of foods for long time without being damaged (2). These materials include antioxidants, food coloring agents, anti-infectious agents, flavoring agents and the most

important one is sodium benzoate (3). Sodium benzoate SB, is white in color, odorless crystallized and found as a grain or powder easily crystallized in appearance and found as powder or grain, water-soluble and in ethanol, it is slightly dissolved. (4). It can be used in a number of foods, including fruit juices, fruit-based fillings, pickles, salad dressings, jams, and carbonated beverages, as well as cosmetics (5). SB has been used as a therapeutic agent in medical applications. (6). Sodium benzoate has the E number E211 and is used as a preservative and food additive. Under acidic conditions, it is bacteriostatic and fungi static. When this compound is consumed inadvertently by the human as food additives, it has harmful

effects on the body (7). Benzoic acid and sodium benzoate are on the Food and Drug Administration's FDA list of generally accepted as safe drugs in the United States GRAS. With a current maximum level of 0.1 percent in food, both can be used as antimicrobial agents, flavoring agents, and adjuvants (7). The FDA hasn't decided whether or not substantially different terms of use are GRAS (3). While sodium benzoate is considered a healthy preservative, excessive ingestion of these preservatives could be harmful to consumers. Excessive use of SB has been linked to changes in serum clinical parameters, according to many studies, research has declared that when SB combines with vitamin C in soft drinks to create benzene, sodium benzoate has been linked to cancer. Also, the study observed that giving this material to the pregnant female rats by mouth led to change in the hypothalamus of the new generation and this case causes change in secretion of growth hormone, thus inverse some effects on the animal's weights (8). Moreover, SB can cause neurotoxicity, nephrotoxicity, and teratogenicity in zebra fish larvae during early embryogenesis (9). The aim of this research was to see how long-term SB administration affects health on some biochemical, physiological and histopathological parameters in adult male albino rats.

## Materials and Methods

### Experimental animals

In this study, 24 male albino rats have been used at age of 100 days and their weights 250 to 350 g. They have been obtained from animal house in the college of Veterinary Medicine/University of Mosul. Feeding *ad libitum*.

### Experimental protocol

Twenty-four adult male rats were divided into four groups. Each group included 6 rats. All treatments were given orally daily by gavage needle for 30 days as T<sub>1</sub> control group given normal saline, T<sub>2</sub>, T<sub>3</sub> and T<sub>4</sub> treatment with sodium benzoate prepared by dissolving it in normal saline at concentration 300, 400 and 500 mg/kg respectively.

### Blood samples collection

After 30 days of treatment, Blood samples were obtained from retro orbital sinus by glass capillaries and collected in plain tubes and allow the sample for coagulation then centrifuged at 3000 rpm for 15 min. Serum samples were immediately stored at -20°C in eppendorf tubes till used for analysis of biochemical parameters (10).

### Biochemical analyses

Blood Serum nitric oxide NO and super oxide dismutase SOD activity, markers of oxidative stress were estimated using kits from Al-shkairate establishment for medical supply. Sweilleh Amman 11910 Jordon. serum growth

hormone (GH) level was measured using COBAS e 411 analyzer- Roche diagnostics.

### Physiological and histopathological examination

After blood collection, internal organs weight liver, heart, kidneys, spleen and brain were recorded. Then the Liver and Brain was placed in solution of 10% formalin for a period of 24 hours for fixation, after that the tissues were dehydrated using a gradual concatenations of alcohol solution 50% - 100% for 5 minute each. Then the tissue samples were cleared in 2 separated xylene changes prior to placing them in paraffin wax for final sectioning. Later the samples were sectioned at 5 µm thickness, then it stained by hematoxylin and eosin stain to study the histological changes compared to the control group using light microscope (11).

### Statistical analysis

The results were expressed as Mean±SEM standard error of the mean. Data were analyzed by one-way analysis of variance ANOVA and were performed using the minitab 18 program, The Tukey's test was used to compare significance between groups. The significance level was accepted at P<0.05 (12).

## Results

### Biochemical test

The results indicated a significant reduction in super oxide dismutase activity in treated groups with increasing sodium benzoate dose compared to the control group. Moreover, the study revealed that there were no significant changes in the growth hormone level of all groups (Table 1).

Table 1: Effect of sodium benzoate on growth hormone (GH) level, SOD activity and NO level

	Mean ± SE (n=6) for 30 days		
	GH pg/ml	SOD µmol/L	NO µmol/L
T1	32.51±2.03A	183.38±5.53A	107.09±0.520B
T2	51.01±8.16A	149.27±4.02B	112.17±1.42B
T3	43.60±5.06A	125.15±2.00C	113.14±0.623B
T4	41.01±5.86A	109.92±1.34D	141.44±5.80A

Different letters vertically mean difference between groups at probability level P<0.05.

The present study revealed a non-significant changes in body weight of treated group with sodium benzoate 300 mg/kg bw in comparison with control and other treated groups, and a significant decrease in heart weight of treated group with sodium benzoate 500 mg/kg bw in comparison with the control and other treated groups. While no significant changes can be observed in the liver, spleen, kidneys and brain weights (Table 2).

Table 2: Sodium benzoate's effect on body, liver, heart, kidney, spleen and brain weights in adult male rats

	Weight mean(mg/100 g b.w.) ± SE (n=6) for 30 days					
	Body weight	Liver	Heart	Kidney	Spleen	Brain
T1	334±14.55A	10.71±0.70A	1.13±0.07A	1.13±0.08A	1.15±0.11A	1.99±0.13A
T2	376.5±8.88A	12.30±0.84A	1.09±0.03A	1.24±0.06A	1.11±0.13A	2.11±0.12A
T3	342.6±7.61A	12.33±0.90A	1.07±0.04A	1.24±0.06A	1.09±0.09A	1.91±0.11A
T4	328.8±16.61A	10.57±0.59A	0.89±0.04B	1.21±0.09A	0.96±0.12A	1.82±0.08A

Different letters vertically mean difference between groups at probability level P<0.05.

### The histopathological results

The study revealed in comparison with control group (Figures 1 and 2) to normal architecture of the cortex of brain with mild vasogenic edema (Figure 3) and shows focal gliosis and satellitosis in the cortex of brain (Figure 4) in group treated with 300 mg/kg.bw of sodium benzoate. In addition, observed mild vacuolation, gliosis and satellitosis in the cortex of brain (Figure 5), and mild vacuolation, gliosis and vasogenic edema in the cortex of brain (Figure 6) in group treated with 400 mg/kg.bw of sodium benzoate.

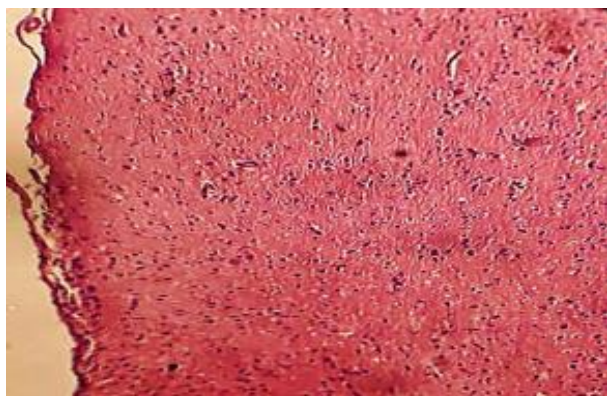


Figure 1: photomicrograph of rat's brain of control group shows normal architecture of the cortex of brain.

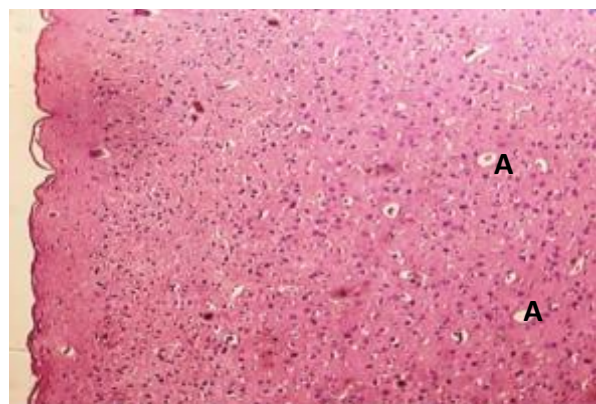


Figure 2: photomicrograph of rat's brain of control group shows normal architecture of the thalamus region of brain.

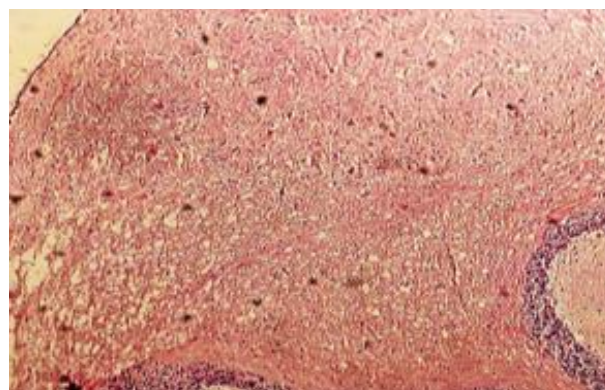


Figure 3: photomicrograph of rat's brain of group T2 shows normal architecture of the cortex with mild vasogenic edema (A).

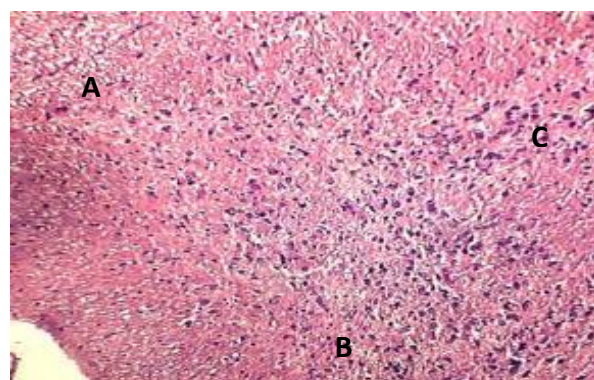


Figure 4: photomicrograph of rat's brain of group T2 shows focal gliosis (A) and satellitosis (B) in the cortex.

Moreover, showed diffuse gliosis, vacuolation, satellitosis and vasogenic edema in the cortex of brain (Figure 7) in group treated with 500 mg/kg bw of sodium benzoate. On the other hand noticed some changes in the liver tissue that was investigating in congestion of portal vein, mild hydropic degeneration of hepatocytes and stenosis of sinusoids (Figure 8) in group treated with 300mg/kg.bw of sodium benzoate, and shows congestion of portal vein, hydropic degeneration of hepatocytes, necrosis of others and stenosis of sinusoids (Figure 9) in group treated with 400 mg/kg.bw of sodium benzoate, in addition shows severe hydropic degeneration, fatty change steatosis,

necrosis of hepatocytes and congestion of portal vein (Figure 10) in group treated with 500 mg/kg bw of sodium benzoate, in comparison of control group (Figure 11).

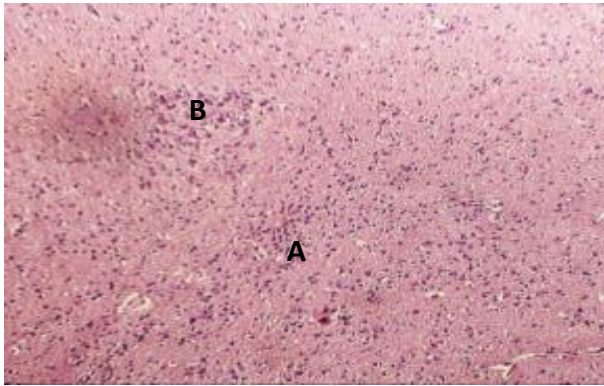


Figure 5: photomicrograph of rat's brain of group T3 shows mild vacuolation (A), gliosis (B) and satellitosis (C) in the cortex.

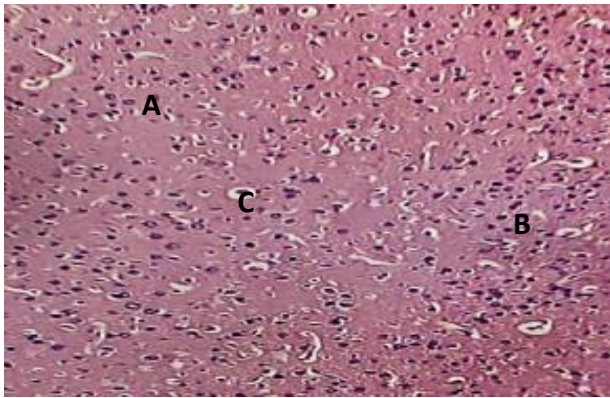


Figure 6: photomicrograph of rat's brain of group T3 shows mild vacuolation (A), gliosis (B) and vasogenic edema (C) in the cortex.

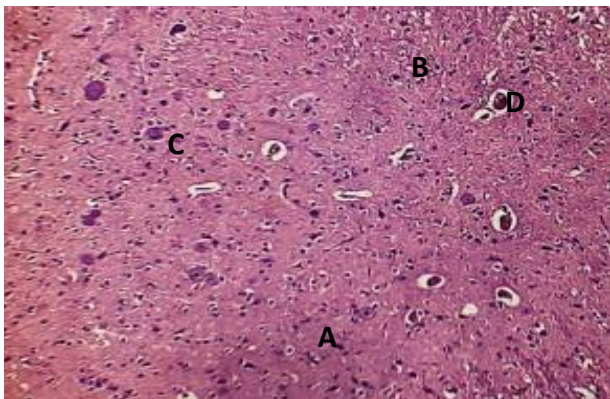


Figure 7: photomicrograph of rat's brain of group T4 shows diffuse gliosis (A), vacuolation (B), satellitosis (C) and vasogenic edema (D) in the cortex.

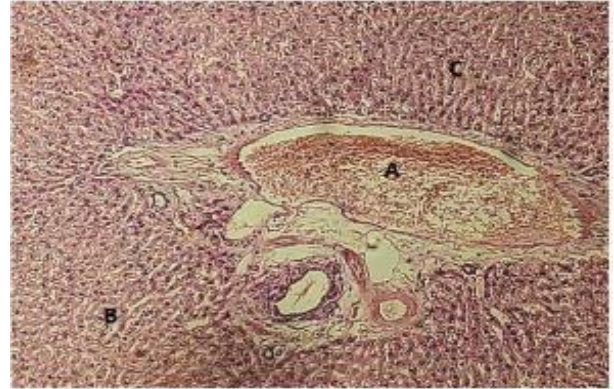

Figure 8: photomicrograph of rat's liver of group T2 shows congestion of portal vein (A), mild hydropic degeneration of hepatocytes (B) and stenosis of sinusoids (C).

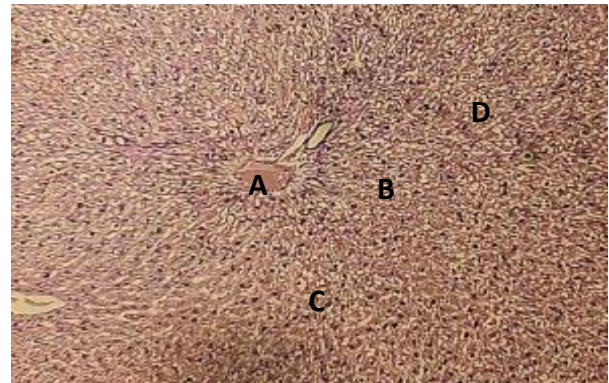


Figure 9: photomicrograph of rats liver of group T3 shows congestion of portal vein (A), hydropic degeneration of hepatocytes (B), necrosis of others (C) and stenosis of sinusoids (D).

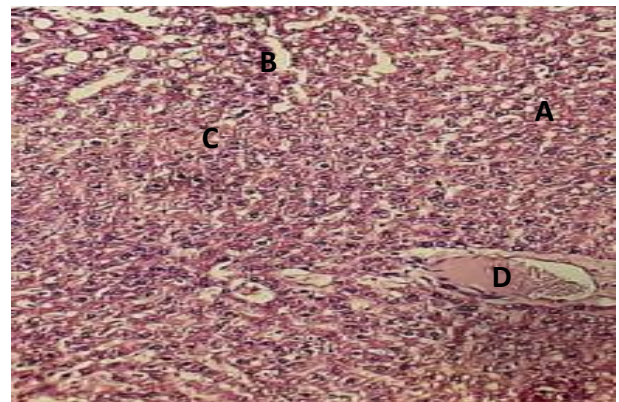


Figure 10: photomicrograph of rat's liver of group T4 shows severe hydropic degeneration (A), fatty change (steatosis) (B), necrosis of hepatocytes (C) and congestion of portal vein (D).

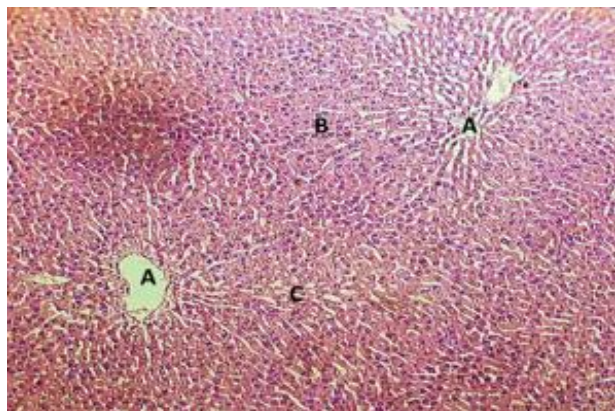


Figure 11: photomicrograph of rat's liver of control group T1 shows normal architecture of liver tissue representing by central veins (A), hepatocytes (B) and sinusoids (C). H&E stain, 100X.

## Discussion

While sodium benzoate is considered a safe chemical, short-term exposure can cause health problems as defect in different organs of the body. Moreover, sodium considers as a basic component in all cell physiology. The disadvantages and side effects of sodium benzoate on human health, including cell damage, have been approved (13), and this research was designed to observe these effects.

The present study revealed no significant changes in body, liver, spleen, kidneys and brain weights, with a significant reduction in heart weight in treated group with 500 mg/kg sodium benzoate. This result agrees with (8,14), benzoate treatment did not alter body weight when compared to control. While the current result didn't agree with (15,16), who found a significant decrease in rat's body weight treated with sodium benzoate. The obtained results may be attributed to a non-significant alteration in growth hormone levels that determined in this research.

This result was not consistent with Hela *et al.* (16), who showed the administration of food additives mixture to rats increased serum thyroid hormones T3 and T4 levels, may be due to alteration in thyroid hormones might result in pituitary-thyroid axis.

On the other hand, the present study refers to a significant decrease in the superoxide dismutase activity in sodium benzoate treated groups and this reduction reverses in a manner proportional to the increasing of sodium benzoate doses.

On the other hands, nitric oxide levels were increased in group treated with 500 mg/kg.bw of sodium benzoate, suggested that sodium benzoate acts as oxidant material and induced oxidative stress (8,17,18).

The histological effects, the outcomes refer to changes occurred in the brain cortex such as focal gliosis, satellitosis, mild vacuolation and vasogenic edema in treated groups with sodium benzoate in different doses and

the changes ranging from mild to severe. Also observed some changes in liver represented by portal vein congestion, mild hydropic degeneration of hepatocytes, stenosis of sinusoids, fatty change steatosis and hepatocytes necrosis with sodium benzoate treatment groups in compared to control group the moderate to severe vacuolation of seminiferous tubule of testes in treated groups with sodium benzoate (19).

Salah *et al.* (20) that showed vacuolation of hepatocytes, congestion of the central vein. Moreover, apoptosis, and necrosis of some hepatocytes in pregnant mice injected (IP) with a Platinum drug at the dose of 3 mg/kg of bw.

## Conclusion

Short term adult male rat's exposure to high doses of sodium benzoate might act as oxidant material, inducing oxidative stress and cell damage. The preservative material can cause defects in different organs of the body.

## Acknowledgments

The authors are very grateful to the University of Mosul, Veterinary College, animal house staff for their provided facilities which helped us to completion this work.

## Conflicts of interest

No conflicts

## References

1. Tawfeeq FK, Jirjees IH. Effect on monosodium glutamate on pregnant female rats and embryo. Al- Anbar J Vet Sci. 2013;6(2):100-107. [\[available at\]](#)
2. Makwana S, Choudhary R, Dogra N, Kohli P, Haddock J. Nano encapsulation and immobilization of cinnamaldehyde for developing antimicrobial food packaging material. Food Sci Technol. 2014;57(2):470-6. DOI: [10.1016/j.lwt.2014.01.043](#)
3. Piper JD, Piper PW. Benzoate and sorbate salts: A Systematic review of the potential hazards of these invaluable preservatives and the expanding spectrum of clinical uses for sodium benzoate. Comp Rev Food Sci Food Safty. 2017;16:868-880. DOI: [10.1111/1541-4337.12284](#)
4. Hadi MM, Mahdi WTh. The effect of sodium benzoate as a preservative on the reproductive system of male rats. Int J Res Sci. 2019;10(1):98-105. DOI: [10.26452/ijrps.v10i1.1785](#)
5. Noorafshan A, Erfanizadeh M, Karbalay SD. Sodium benzoate, a food preservative, induces anxiety and motor impairment in rats. Neuro Sci. 2014;19 (1):24-28. [\[available at\]](#)
6. Inetianbor JE, Yakubu JM, Ezeonu SC. Effects of food additives and preservatives on man- a review. Asia J Sci Technol. 2015;6(2):1118-1135. [\[available at\]](#)
7. Shahid M, Alwan NA, Al-Masoudi EA. A study of toxic effect of sodium benzoate, vitamin C alone and their combination on reproductive functions of adult male rabbits. Bas J Vet Res. 2018;17(3):533-543. [\[available at\]](#)
8. Khoshnoud MJ, Siavashpour A, Bakhshizadeh M, Rashedinia M. Effects of sodium benzoate, a commonly used food preservative on learning memory and oxidative stress in brain of mice. J Biochem Mol Toxicol. 2017;94(01):1-7. DOI: [10.1002/jbt.22022](#)

9. Tsay HJ, Wang YH, Chen WL, Huang MY, Chen YH. Treatment with sodium benzoate leads to malformation of zebra fish larvae. *Neurotoxicol Teratol.* 2007;29(5):562-9. DOI: [10.1016/j.ntt.2007.05.001](https://doi.org/10.1016/j.ntt.2007.05.001)
10. Ahmed MA. Protective effect of aqueous extract of *Alhagi maurorum* in spermatogenesis and antioxidant status of adult rats exposed to carbon tetrachloride. *Iraqi J Vet Sci.* 2019;33(1):1-7. DOI: [10.33899/ijvs.2019.125509.1031](https://doi.org/10.33899/ijvs.2019.125509.1031)
11. Al-Jammas S, Al-Saraj A. The histological changes induced by cytarabine on rabbits livers (with and without vitamin E administration). *Iraqi J Vet Sci.* 2020;34(1):9-13. DOI: [10.33899/ijvs.2020.163564](https://doi.org/10.33899/ijvs.2020.163564)
12. Hamzah FZ, Al-Sharafi NM, Kasim SF. Effect of aqueous rosemary extract on some sexual hormones in male rats with high thyroxine level. *Iraqi J Vet Sci.* 2021;35(2):369-373. DOI: [10.33899/ijvs.2020.126872.1404](https://doi.org/10.33899/ijvs.2020.126872.1404)
13. Hartwig A. Benzoic acid and alkali benzoates. *Occupat Hlth Safety.* 2018;3(4):1758-1828. DOI: [10.1002/3527600418.mb6585e6318](https://doi.org/10.1002/3527600418.mb6585e6318)
14. Kehinde OS, Christianah OI, Oyetunji OA. Ascorbic acid and sodium benzoate synergistically aggravates testicular dysfunction in adult Wistar rats. *Int J Physiol Pathophysiol Pharmacol.* 2018;10(1):39-46. [\[available at\]](#)
15. Helal EE, El-Sayed RA, Hedeab GM, El-Gamal MS. Effects of some food additives on some biochemical parameters in young male albino rats and the ameliorative role of royal jelly. *Egypt J Hospit Med.* 2017;67(2):605-613. DOI: [10.12816/0037812](https://doi.org/10.12816/0037812)
16. Helal EG, Barayan AW, Abdelaziz MA, EL-Shenawe NS. Adverse effects of mono sodium glutamate, sodium benzoate and chlorophyllins on some physiological parameters in male albino rats. *Egypt J Hospit Med.* 2019;74(8):18571864. DOI: [10.21608/ejhm.2019.28865](https://doi.org/10.21608/ejhm.2019.28865)
17. Ansari FA, Ali SN, Arif H, Khan AA, Mahmood R. Acute oral dose of sodium nitrite induces redox imbalance, DNA damage, metabolic and histological changes in rat intestine. *PLoS ONE.* 2017;12(4):175-196. DOI: [10.1371/journal.pone.0175196](https://doi.org/10.1371/journal.pone.0175196)
18. Moeen SS, Elhalwagy MA, Ayaz NO. Alterations in oxidative stress and antioxidant in albino rats treated with individual and combined various food additives. *Int J Adv Res Biol Sci.* 2018;5(6):118-123. DOI: [10.22192/ijarbs.2018.05.06.011](https://doi.org/10.22192/ijarbs.2018.05.06.011)
19. Oladele JO, Oladele OT, Ademiluyi AO, Oyeleke OM, Awosanya OO, Oyewole OI. Chaya (*Jatropha tanjorensis*) leaves protect against sodium benzoate mediated renal dysfunction and hepatic damage in rats. *Clin Phytosci.* 2020;6:13. DOI: [10.1186/s40816-020-00160-5](https://doi.org/10.1186/s40816-020-00160-5)
20. Salah BA, Sadoon HS. Histopathological and some biochemical effects of platinum drug on the liver and kidney of pregnant mice *Mus musculus* and their embryos. *Iraqi J Vet Sci.* 2021;35(2):291-300. DOI: [10.33899/ijvs.2020.126706.1364](https://doi.org/10.33899/ijvs.2020.126706.1364)

## تأثير بنزوات الصوديوم على بعض الجوانب الكيموحيوية والفسلجية والنسجية في ذكور الجرذان البالغة

صفاء عبد العزيز الامين<sup>١</sup>، إيمان حازم جرجيس<sup>٢</sup>  
و فدوى خالد توفيق<sup>٣</sup>

<sup>١</sup>قسم الكيمياء، كلية العلوم، جامعة الموصل، <sup>٢</sup>قسم تقنيات صناعة أسنان، كلية النور الجامعة، <sup>٣</sup>فرع الفسلجة والكيمياء الحياتية، كلية الطب البيطري، جامعة الموصل، الموصل، العراق

### الخلاصة

تستخدم بنزوات الصوديوم بصورة واسعة كمادة حافظة ومضاد غذائي للكثير من الأطعمة ويعتقد أن التعرض لفترة طويلة لهذه المادة وزيادة تراكيزها في الدم يؤدي إلى تأثيرات جانبية على صحة الإنسان وأعضائه الحيوية. تضمن البحث إمكانية اختبار التأثيرات الكيموحيوية والفسلجية والنسجية لبنزوات الصوديوم في ذكور الجرذان البالغة، حيث تم استخدام ٢٤ منها تتراوح أوزانها بين ٢٥٠-٣٥٠ غم، تم تقسيمها إلى ٤ مجاميع. اعتبرت المجموعة الأولى مجموعة سيطرة تلقت المحلول الملحي عن طريق الفم في حين أخضعت المجموعات الثلاثة الأخرى للمعاملة ببنزوات الصوديوم بالجرع ٣٠٠، ٤٠٠ و ٥٠٠ ملغم/كغم على التوالي لمدة ٣٠ يوماً، ثم جمعت عينات الدم من محجر العين لتقدير أوكسيد النترريك وفعالية إنزيم فوق أوكسيد الدسميونيز ونشاط هرمون النمو في مصّل الدم. أظهرت النتائج وجود زيادة معنوية في تركيز أوكسيد النترريك وانخفاض معنوي في فعالية إنزيم فوق أوكسيد الدسميونيز في مصّل الدم للمجموعة المعاملة بالجرعة ٥٠٠ ملغم/كغم مقارنة بمجموعة السيطرة، بينما لم تظهر النتائج وجود فرق معنوي في فعالية هرمون النمو ووزن الجسم. كذلك أشارت النتائج إلى وجود انخفاض معنوي مقارنة بمجموعة السيطرة في وزن القلب للمجموعة المعاملة ببنزوات الصوديوم بالجرعة ٥٠٠ ملغم/كغم. علاوة على ذلك، أظهر الفحص النسجي تغيرات تتراوح بين خفيفة إلى شديدة في قشرة الدماغ مثل الدباق البؤري والتسائل والوذمة الوعائية في المجموعات المعاملة ببنزوات الصوديوم بالجرع ٣٠٠، ٤٠٠ و ٥٠٠ ملغم/كغم. أخيراً لا بد من الإشارة إلى وجود بعض التغيرات في الكبد متمثلة باحتقان الوريد البابي والتكس المائي وتضيق الجيوب والتكس الدهني والنخر في خلاياه للمجاميع الثلاثة المعاملة ببنزوات الصوديوم مقارنة بمجموعة السيطرة.