

Onychomycosis Due to *Fusarium oxysporum* in Sulumaniyah City, Iraq

SAZAN JAMAL GHARIB¹, SAMIR KHALAF ABDULLAH²

CC BY-NC-ND

ABSTRACT

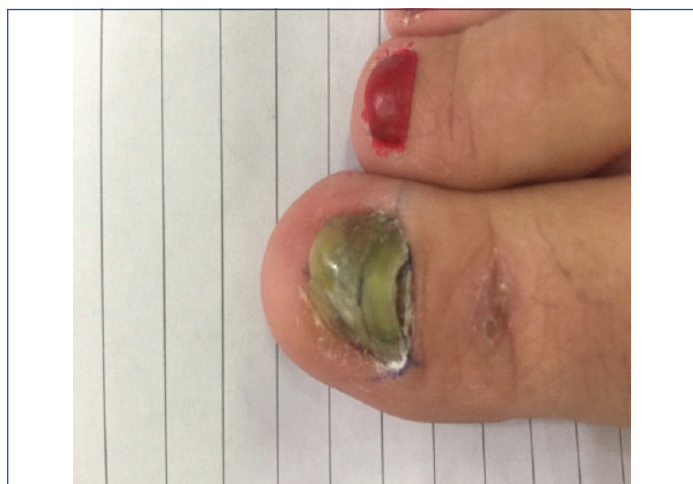Onychomycosis is a fungal infection of the nail plate of fingernails or toenails that is caused by dermatophytes, non-dermatophyte filamentous fungi or yeasts. An opportunistic pathogenic fungus was isolated from toenail of a 38-year-old female with newly diagnosed Acute Myeloid Leukaemia (AML) which appeared to belong to the genus *Fusarium*. Identification of aetiologic agent was performed by morphological and cultural characteristics and was confirmed by sequencing of the Internal Transcribed Spacer (ITS) region of rDNA. The isolated *Fusarium oxysporum* in this paper is the first case of its kind to be sequenced and reported by molecular method in Iraq.

Keywords: Fungal infection, Molecular sequencing, Nail infection

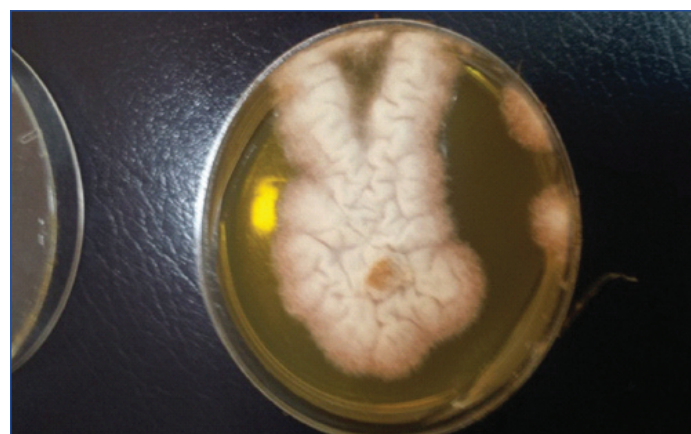CASE REPORT

A 38-year-old female, was referred to the Dermatology out-patient clinic of Hiwa hospital (Sulumaniyah city, Iraq) in October 2016. That was the first visit of the patient to the clinic. She did not give any previous history for her case. On examination, right first toenail was dark yellowish-green to brown in colour with loss of texture and there were dystrophic changes in the nail plate of first toenail [Table/Fig-1]. The associated factor in this case was newly diagnosed acute myelogenous leukaemia for 10 months duration, and at the time of sampling, the patient had undergone chemotherapy. At day 1, oral itraconazole (200 mg/day) for two consecutive months was recommended by physician at Hiwa hospital (Sulumaniyah city, Iraq). Unfortunately, the patient did not visit the hospital; hence further management was not possible.

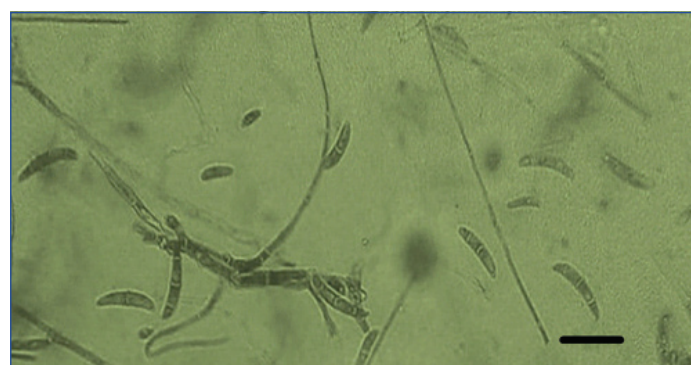
(SDI) (250 mg/L), and cycloheximide) (Sigma-Aldrich) (500 mg/L), and one slant of SDA contained antibiotics but without cycloheximide, which were incubated at 30°C and examined after seven days for fungal growth. The mycological test of the case, which included direct KOH examination before specimen culture was considered positive for the right first toenail. This was evident by presence of numerous hyaline branched and septate hyphae and reproductive structures suggestive of chlamydospores. Microscopic mounts were made in Lactophenol Cotton Blue (LPCB) from the white, cottony culture which later turned pink in colour examined after 10 days incubation on SDA at 30°C. The causative agent was identified as *Fusarium oxysporum* according to The *Fusarium* Laboratory Manual [Table/Fig-2,3] [2].



[Table/Fig-1]: Dystrophic changes in the nail plate and extensive yellowish-green discoloration of large first toenail.



[Table/Fig-2]: *Fusarium oxysporum*: white colony turned pink in colour on SDA medium.



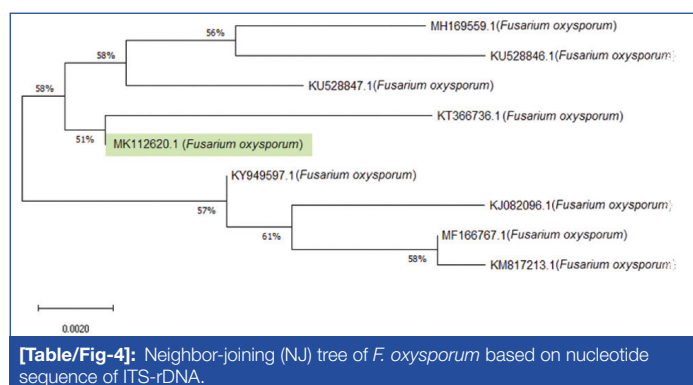
[Table/Fig-3]: LPCB wet mounts showing slightly curved hyaline septate macroconidia and oval or kidney shaped microconidia. Bar = 10 µm.

Nail clippings from the affected right great toenail was collected after proper sterilisation of the affected area with 70% alcohol. The sample was divided into two portions; one portion was observed through direct microscopic examination by mounting in 1-2 drops of 20% potassium hydroxide (KOH) solution (Merck, Germany) for 15-30 minutes, gently heated, then viewed under the light microscope (CX 40 Olympus USA) to look for fungal structures (hyaline hyphae, macro and/or micro conidia and chlamydospore) [1]. Remaining portion of the nail clippings was cultured on two sets of Sabouraud's Dextrose Agar (SDA) medium (CM41; Oxoid, UK): two replicates of SDA plates with antibiotics chloramphenicol

The method for genomic DNA extraction of the isolated *F. oxysporum* strain was performed as described by Gharib SJ et al., [3]. Genomic DNA was extracted and purified by taking a proper amount from fresh colony (21-day-old, grown on SDA dishes) by grinding in presence of liquid nitrogen for initial breaking up of mycelia. Total DNA isolation of fungi achieved using molecular biology kit (EZ-10 Spin Column Fungal Genomic DNA Mini-preps Kit, BIO BASIC INC., Canada) according to the instruction recommended by the manufacturer.

The ITS1-ITS4 primer pair was used to amplify the inverting 5.8S ribosomal DNA and the adjacent ITS1 and ITS2 regions. The ITS region on rDNA was amplified by using universal primers ITS1-(5'-TCCGTAGGTGAACCTGCGG-3') and ITS4 (5'-TCCTCCGCTTATTGATATGC-3') (MWG-Biotech AG, Germany) which resulted in PCR product size of 471 bp for *Fusarium oxysporum*. Thermocycling program for isolated fungus was done in a GenAmp9700 thermal cycler (Perkin-Elmer) as following conditions: An initial denaturation set up at 94°C for 5 minutes was followed by 35 cycles of denaturation at 94°C for 1 minute annealing at 58°C for 1 minute and extension at 72°C for 1 minute with a final extension step of 72°C for 10 minutes. The PCR products were analysed by electrophoresing 10 µL of amplicons in 2% (w/v) agarose gel in TBE buffer {90 mM Tris, 90 mM boric acid, 2 mM EDTA, pH 8.3}, stained with ethidium bromide and supplied to the power at 75 volts for 90 minutes. The gel was visualised under computerised UV trans-illuminator and photographed. A 100 bp DNA marker was used as a reference to determine the size of fragments.

PCR product was sequenced by Macrogen Company (South Korea). The ITS sequences of our isolate (MK112620) have been deposited in GenBank (NCBI). Used BLAST search tool, to compare the resulting sequences with sequences of rDNA accessed in Genbank, the phylogenetic analysis for *F. oxysporum* showed that the obtained sequences shares 99% homology to *Fusarium oxysporum* strains: Indian isolates (KY949597, KM817213, MH169559 and MF166767), Tunisian isolates: (KU528846 and KU528847) and Chinese isolates: (KT366736 and KJ082096) [Table/Fig-4]. Together, morphological identification and molecular identification showed that *Fusarium* isolate was *F. oxysporum* (Genbank accession no. MK112620).



DISCUSSION

Fusarium species are among the common hyaline non-dermatophytic causal agents related to onychomycosis [4]. Onychomycosis can be caused by several species of *Fusarium* such as *F. oxysporum*, *F. solani*, *F. moniliforme* and *F. subglutinans* [5]. The former two species were reported as the commonest among the genus as causal agents of onychomycosis [6].

According to studies by Balajee SA et al., on medically important Fusaria, revealed the presence of multiple cryptic species within each morphospecies [7], therefore, *Fusarium oxysporum* represents a complex. However, the ITS region is acceptable tool for identification of *F. oxysporum* [8].

Fusarium oxysporum complex is an a ubiquitous worldwide soil-borne facultative parasite inhabiting soil and plant debris [9], some isolates are well known plant pathogenic fungi mostly causing wilt diseases to a wide host range of vascular plants [10]. The fungus is also known as opportunistic pathogens to human and animals causing mostly superficial infections [11] as well as reported in disseminated infections mostly in immunocompromised patients [12]. Incidence of onychomycosis due to *Fusarium oxysporum* was commonly reported worldwide [6,13-15]. Several cases of onychomycosis due *F. oxysporum* were reported in immunocompetent and immunocompromised patients [16-18]. Present case study of onychomycosis was found in a 38-year-old female newly diagnosed with (of 10 months duration) acute myelogenous leukaemia. In Iraq, however, few studies have been published on onychomycosis and their aetiologic agents. Abdullah SK et al., diagnosed *Epidermophyton floccosum*, *Trichophyton verrucosum*, *T. violaceum*, *Candida albicans*, *C. famata*, *C. parapsilosis* and *Geotrichum candidum* as pathogens causing onychomycosis among patients from Basrah province, south Iraq [19]. In a subsequent study, Muhsin TM et al., reported *C. albicans*, *C. parapsilosis* and *C. tropicalis* as the frequent aetiologic agents of onychomycosis from the same city [20]. Hafidh RR and Abdulmir AS reported a case of white superficial onychomycosis related to *Cladosporium* sp. in patients from Baghdad [21]. *Malassezia furfur* was reported with 12% incidence as aetiologic agent in patients from Baghdad [22] and *Fusarium* sp. was reported with 33.3% in female patients from Tikrit city [23]. More recently, *Auxarthron alboluteum* was reported as aetiologic agent of toenail infection in a 63-year-old female patient from Kurdistan region of Iraq [3].

CONCLUSION(S)

In the present case, *Fusarium oxysporum* was reported as a new aetiologic agent of onychomycosis in Iraq. Identification of the species was confirmed by microscopic examination and sequencing of the ITS region of rDNA.

REFERENCES

- [1] Kane J, Summerbell RC, Sigler L, Kraiden SL. Laboratory handbook of dermatophytes. Belmont CA: Star Publishers.1997.
- [2] Leslie JF, Summerell BA. The *Fusarium* Laboratory Manual. Blackwell Publishing, Ames, Iowa, USA. 2006.
- [3] Gharib SJ, Abdullah SK, Richardson MD. *Auxarthron alboluteum* related to non-dermatophytic toenail infection in Kurdistan region, Iraq: A case report. Medical Mycology Case Reports. 2019;26:53-56.
- [4] Rankawaka RR, Nagahawatte A, Gunasekara TA. *Fusarium* onychomycosis: Prevalence, clinical presentations, response to itraconazole and terbinafine pulse therapy, and 1-year follow-up in nine cases. Int J Dermatol. 2015;54(11):1275-82.
- [5] Gaviria-Rivera A, Giraldo-Lopez A, Santa-Cardona C, Cano-Restrepo L. Molecular identification of clinical isolates of *Fusarium* in Colombia. Rev Salud Publica. 2018;20(1):94-102.
- [6] Godoy P, Nunes F, Silva V, Tomimori-Yamashita J, Zoror L, Fischman O. Onychomycosis caused by *Fusarium solani* and *Fusarium oxysporum* in Sao Paulo, Brazil. Mycopathologia. 2004;157:287-90.
- [7] Balajee SA, Borman AM, Brandt ME, Cano J, Guenca-Esterella M, Dannaoui E, et al. Sequence based identification of *Aspergillus Fusarium* and *Mucorales* species in the clinical mycology laboratory: Where are we and where should we go from here. J Clin Microbiol. 2009;47(4):877-84.
- [8] Irrnyi I, Serena C, Garcia-Hermosa D, Arabatzis M, Desonos-Ollivier M, Uv D, et al. International Society of Human and Animal Mycology (ISHAM)-ITS reference DNA barcoding database- the quality controlled standard tool for routine identification of human and animal pathogenic fungi. Medical Mycology. 2015;53(4):313-37.
- [9] Domsch KH, Gams W, Anderson TH. Compendium of soil fungi. Academic Press, London. 1980.
- [10] Armstrong GM, Armstrong JK. *Formae speciales* and races of *Fusarium oxysporum* causing wilt disease. In: Nelson PE, Toussoun TA and Cook RJ (Eds), *Fusarium: Disease, Biology, and Taxonomy*. Pennsylvania State University Press, pp. 391-99. 1981.
- [11] Gupta AK, Baran R, Summerbell RC. *Fusarium* infections of the skin. Curr Opin Infect Dis. 2000;13(2):121-28.
- [12] Nucci M, Anaissie E. *Fusarium* infections in immunocompromised patients. Clin Microbiol Rev. 2007;20(4):695-704.
- [13] Rush-Munro FM, Black H, Dingley JM. Onychomycosis caused by *Fusarium oxysporum*. Australasian Journal of Dermatology. 1971;12(1):18-29.
- [14] DiSalvo AF, Fickling AM. A case of nondermatophytic toe onychomycosis caused by *Fusarium oxysporum*. Arch Dermatol. 1980;116(6):699-700. Doi:10.1001/archderm.1980.01640300087027
- [15] Romano C, Miracco C, Difonza EM. Skin and nail infections due to *Fusarium oxysporum* in Tuscany, Italy. Mycoses. 1998;41(9-10):433-37.

- [16] Guilhermetti E, Takahachi G, Shinobu CS, Svidzinski TIE. *Fusarium* species as agents of onychomycosis in immunocompetent hosts. *Int J Dermatol*. 2007;46(8):822-26.
- [17] Shah SR, Dalal BD, Modak MS. Nondermatophytic onychomycosis by *Fusarium oxysporum* in an immunocompetent host. *Journal de Mycologie Medicale*. 2016;26:e18-e21.
- [18] Carvalho VO, Vicente VA, Werner B, Gomes RR, Fornari G, Herkert PF, et al. Onychomycosis by *Fusarium oxysporum* probably acquired in utero. *Medical Mycology Case Reports*. 2014;6:58-61.
- [19] Abdullah SK, Al-Hamdani FM, Naama MS. Incidence and aetiologic study of onychomycosis in Basrah, Iraq. *Iraqi Journal of Biology*. 2002;2(2):464-68.
- [20] Muhsin TM, Al-Rubaiy, Al-Duboon. Characteristics of dermatophytoses in Basrah, Iraq. *Mycoses*. 2002;335-38. Available at: <https://doi.org/10.1046/j.1439-0507.1999.00463.x>.
- [21] Hafidh RR, Abdulmir AS. *Cladosporium* spp. as a causative agent of white superficial onychomycosis. *East Mediterr Health J*. 2008;14(1):231-33.
- [22] Ammari AM, Talib NT, Hussein AF, Abdul-Rahman ES. Association of *Malassezia furfur* with onychomycosis patients in Baghdad, Iraq. *Diyala Journal of Medicine*. 2018;14(1):115-22.
- [23] AL-Tikrity Thekra A, AL-Juboor Osama M. Onychomycosis in females; a clinicomycological study. *Tikrit Medical Journal*. 2011;17(1):43-44.

PARTICULARS OF CONTRIBUTORS:

- Lecturer, Department of Medical Laboratory, Sulumaniyah Technical Institute, Sulumaniyah Polytechnique University and Biology Department, University of Zakho, Iraq.
- Professor, Department of Medical Laboratory Technology, [Alnoor University College, Bartila, Nineva, Iraq](#).

NAME, ADDRESS, E-MAIL ID OF THE CORRESPONDING AUTHOR:

[Dr. Samir Khalaf Abdullah](#),
 Department of Medical Laboratory Technology, [Alnoor University College](#),
 Bartila, Nineva, Iraq,
 E-mail: samir.abdullah1947@gmail.com

PLAGIARISM CHECKING METHODS: [\[Jain H et al.\]](#)

- Plagiarism X-checker: Sep 16, 2019
- Manual Googling: Nov 30, 2019
- iThenticate Software: Dec 28, 2019 (15%)

ETYMOLOGY: Author Origin**AUTHOR DECLARATION:**

- Financial or Other Competing Interests: No
- Was informed consent obtained from the subjects involved in the study? Yes
- For any images presented appropriate consent has been obtained from the subjects. Yes

Date of Submission: **Sep 16, 2019**Date of Peer Review: **Oct 24, 2019**Date of Acceptance: **Dec 10, 2019**Date of Publishing: **Jan 01, 2020**